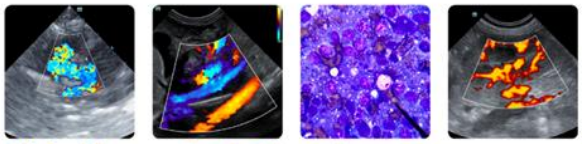

PATIENT
Hondo Worsham

SPECIES
Feline

BREED
DSH

SEX
MN

AGE
3.5yr

WEIGHT
5.4kg

INTERPRETED BY
R. McKenzie Daniel, DVM, DABVP (Canine and Feline)

IMAGING PERFORMED BY
Lindsay Powell, CVT

HOSPITAL NAME
Hershey Animal Emergency Center

REFERRING VET
Dr. Lydia Coogan

INVOICE
24468

DATE
04/13/2026

PRESENTING CLINICAL SIGNS

P threw up a hair ball and food on 4/2. Then he continued to vomit up all food through out that weekend. Went to rDVM on 4/6, radiographs were taken; received SQF and Cerenia SQ. Improved after Cerenia. Started vomiting again 4/9. Today vomited a red tinge to it with possible clots. Abnormal PE/Chem/CBC/UA Results: Initially, extremely painful on abdominal palpation. Now comfortable with pain medication on board. CBC: inflammatory leukogram (WBC 23.57 H, neutrophila 18.63 H) Chem: TP 5.1 (L), albumin 2.3 (low normal) EPOC: BE -6.1 (L) fPL: 10 (H), TP 5.1 (L), albumin 2.3 (low normal) UA: mild proteinuria (30), otherwise unremarkable, USG 1.050 Radiographs: no signs of an intestinal obstruction, empty stomach, diffusely enlarged and fluid filled small intestines, normal stool in colon

ULTRASONOGRAPHIC EXAMINATION OF THE ABDOMEN

Urinary System

The urinary bladder, trigone, cystourethral junction, and visible pelvic urethra exhibited normal thickness and tone. Anechoic urine was present in the lumen with mild to moderate non-dependent particulate sediment. The ureteral papillae were normal. The ureters were not visible which is normal. No evidence of inflammatory or neoplastic changes was noted.

Normal size and margination was present in the kidneys. A normal 1:3 cortex / medulla ratio and normal corticomedullary definition were maintained. The echogenicity of the cortex was similar to or slightly less than normal liver parenchyma while the medulla echogenicity was hypoechoic to the cortex with no evidence of pelvic dilation. A hyperechoic corticomedullary band, consistent with a medullary rim sign, was present. This is a nonspecific finding seen in both normal and abnormal kidneys. It may be associated with interstitial renal disease, hypercalcemia, tubular necrosis, lymphoma, and FIP. However, it is a nonspecific finding. The left kidney measured 4.2 cm in length. The right kidney measured 4.2 cm in length.

The area of the aortic trifurcation was free of pathology.

Adrenal Glands

The left adrenal gland was uniform in size and contour with a uniformly hypoechoic parenchyma. The left adrenal gland measured 0.40 cm width. The right adrenal gland was uniform in size and contour with a uniformly hypoechoic parenchyma. The right adrenal gland measured 0.40 cm width.

Spleen

The spleen exhibited a finely textured and homogenous parenchyma which was hyperechoic to the liver and renal cortical parenchyma. The capsule was smooth and regular without apparent expansion. The splenic vasculature at the hilus was normal in volume with no evidence of congestion or thrombosis. Acute to chronic inflammatory, neoplastic, or benign parenchyma changes were not noted.

Liver/Gallbladder

The liver was subjectively normal in size, structure, and contour. The liver parenchyma was uniform and hypoechoic to the spleen with a mild coarse echotexture. Normal vascular volume. The hepatic and portal vasculature were normal in appearance without signs of congestion. The gallbladder was non-distended in size with thin walls and primarily anechoic luminal content. The cystic and common bile ducts were normal.

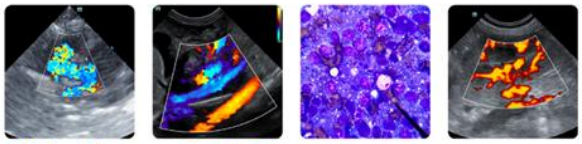

PATIENT
Hondo Worsham

SPECIES
Feline

BREED
DSH

SEX
MN

AGE
3.5yr

WEIGHT
5.4kg

INTERPRETED BY
R. McKenzie Daniel, DVM, DABVP (Canine and Feline)

IMAGING PERFORMED BY
Lindsay Powell, CVT

HOSPITAL NAME
Hershey Animal Emergency Center

REFERRING VET
Dr. Lydia Coogan

INVOICE
24468

DATE
04/13/2026

Gastrointestinal

The stomach presented intact wall layering with a normal wall layer ratio. The lumen of the stomach was empty with no signs of ileus, obstruction or foreign material.

The intestinal walls demonstrated intact wall layers with diffusely thickened walls and altered 1:3 muscularis / mucosa ratio primarily consisting of muscularis hypertrophy. The duodenum wall measured 0.33 cm width. The jejunum wall measured 0.31 cm width.

Normal visible colon wall layers were present with apparent formed feces in lumen.

Pancreas

The pancreas was normal in size with asymmetrical contour and mild non-homogenous hypoechoic parenchyma compared to adjacent omentum.

Free Abdomen

No omental masses, overt lymphadenopathy or peritoneal effusion was present.

ULTRASONOGRAPHIC FINDINGS

Primary

- Sonographically normal empty stomach
- Thickened small intestine exhibiting altered wall layer ratio
- Suspect concurrent low-grade pancreatitis
- Non-specific bilateral renal medullary rim sign
- Urinary bladder sediment

INTERPRETATION OF THE FINDINGS & FURTHER RECOMMENDATIONS

The appearance of the small intestine is compatible with infiltrative enteropathy. Primary considerations may include favored inflammatory infiltrative enteropathy such as IBD, eosinophilic enteritis or other, while potential neoplastic infiltrative enteropathy with round cells such as lymphoma may present in similar sonographic manner, dry form FIP also is a potential yet thought less likely. Diagnosis would require biopsies for histology, obtained either via endoscopy or, ideally, full thickness biopsies via laparotomy. A GI Panel to include PLI/TLI/Cobalamin/Folate is recommended. If additional diagnostics are not elected, empirical medical therapy for IBD which may include dietary therapy, cobalamin supplementation, probiotics +/- steroids trial with assessment of clinical response and monitoring of body weight could be considered.

No evidence of gastric mural pathology, although gastric micro ulceration given potential hematemesis possible. Concurrent gastric protectants are recommended.

The urinary bladder sediment may suggest cellular / crystalline debris or mucus. Cystocentesis for UA +/- C/S if evidence of inflammatory cells is recommended.

SonoPath
FOSTERING THE ART OF VETERINARY MEDICINE™

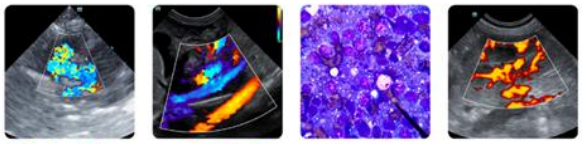

Clinical Sonography & Telecytology
Educational Teleconsultation Services™

SonoPath.com info@sonopath.com 1.800.838.4268

PATIENT

Hondo Worsham

SPECIES

Feline

BREED

DSH

SEX

MN

AGE

3.5yr

WEIGHT

5.4kg

INTERPRETED BY

R. McKenzie Daniel, DVM, DABVP (Canine and Feline)

IMAGING PERFORMED BY

Lindsay Powell, CVT

HOSPITAL NAME

Hershey Animal Emergency Center

REFERRING VET

Dr. Lydia Coogan

INVOICE
24468

DATE
04/13/2026

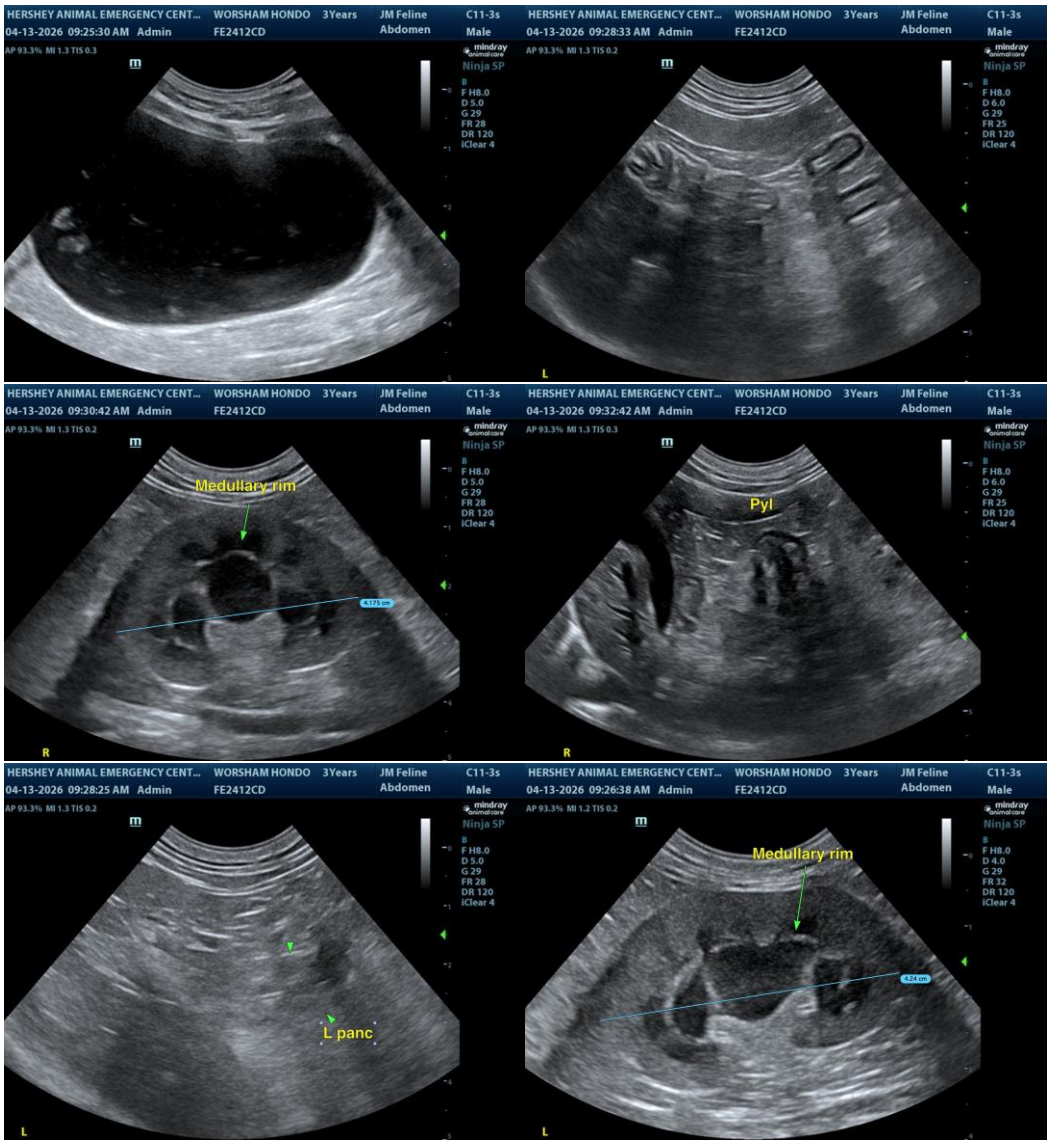

SonoPath
FOSTERING THE ART OF VETERINARY MEDICINE™

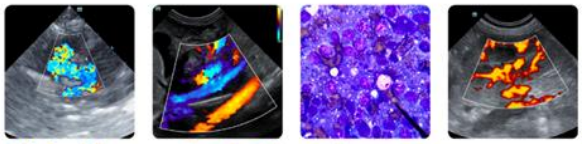

Clinical Sonography & Telecytology
Educational Teleconsultation Services™

SonoPath.com info@sonopath.com 1.800.838.4268

PATIENT

Hondo Worsham

SPECIES

Feline

BREED

DSH

SEX

MN

AGE

3.5yr

WEIGHT

5.4kg

INTERPRETED BY

R. McKenzie Daniel, DVM, DABVP (Canine and Feline)

IMAGING PERFORMED BY

Lindsay Powell, CVT

HOSPITAL NAME

Hershey Animal Emergency Center

REFERRING VET

Dr. Lydia Coogan

INVOICE
24468

DATE
04/13/2026

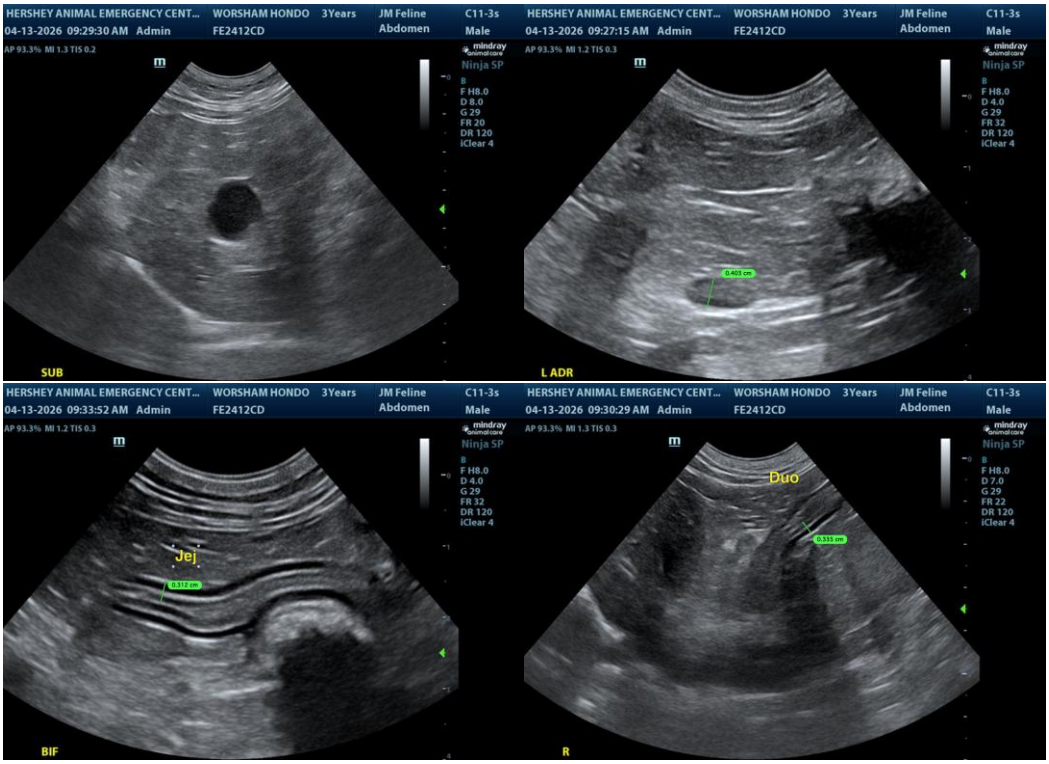

The information and recommendations provided are based on the images presented by the referring veterinarian/sonographer. No evaluation can be communicated regarding pathology that was not visible in the image/video clips provided.

Thank you for this referral. If the clinical or image interpretation does not parallel your findings or if I can be of any further assistance, please contact me.

R. McKenzie Daniel, DVM, DABVP (Canine/Feline Practice)
info@sonopath.com